

Case Report

Capillary hemangioma of tympanic cleft

Authors

Rakesh Kumar Singh,

Ex Assistant Professor, Department of Otolaryngology Head and Neck Surgery,

Sangita Bhandary,

Associate Professor, Department of Otolaryngology Head and Neck Surgery,

Awadhesh Tiwary,

Assistant Professor, Department of Radiology,

Smirti Karki,

Assistant Professors, Department of Pathology

B.P. Koirala Institute of Health Science, Dharan, Nepal

Address For Correspondence

Rakesh Kumar Singh,

Assistant Professor

Department of ENT,

Himalayan Institute of Hospital Trust,

Jollygrant, Doiwala,

Dehradun 248140

E-mail: rksent5@gmail.com

Citation

Singh RK, Bhandary S, Tiwary A, Karki S. Capillary hemangioma of tympanic cleft *Online J Health Allied Scs.* 2008;7(4):8

URL

<http://www.ojhas.org/issue28/2008-4-8.htm>

Submitted: Oct 1, 2008; Accepted: Jan 19, 2009 Published: Feb 25, 2009

Abstract:

We present an extensive capillary hemangioma of right ear in an 11-year-old child involving external auditory canal, middle ear and mastoid. Patient was presented with chronic purulent discharge and aural mass in right ear. The Computerize tomography (CT) scan revealed enhancing soft tissue filled density in external ear, middle ear and mastoid for that modified radical mastoidectomy (MRM) was done. The histopathological report of surgical specimen confirmed the diagnosis of capillary hemangioma

Key Words: Hemangioma, Capillary, Tympanic cleft.

Introduction:

Hemangiomas are well-known, benign, vascular tumor commonly seen in head and neck region.¹ They usually present as a cutaneous lesion around the parotid gland or in the sub-glottis area of larynx. It is extremely rare in external or middle ear.² Only 18 such cases have been reported in English literature and out of which, only one with hemangioma of middle ear was extended to the mastoid cavity. In eight cases, the hemangioma was confined to middle ear while, in other nine cases there were isolate involvement of the external auditory canal and/or tympanic membrane.^{1,3} With best of our knowledge, this is the first case report of tympanic cleft hemangioma simultaneously involving external auditory canal, middle ear and mastoid.

Case Report:

A 11 years old boy was presented to the Otolaryngology clinic of our Institution with a history of right ear discharge since childhood and protruding mass from the same ear for 7 years. The discharge was non-foul smelled, intermittent, purulent, blood staining, increased with upper respiratory tract infection. He also had gradually progressive diminished hearing for last six years. There was no history of tinnitus, vertigo, facial nerve symptoms. The review of systems, medical and surgical history, and family history were unremarkable. The local inspection of ear revealed pale, polypoidal, painless, none bleeding, non-friable mass seems attach to the posterior, superior and anterior wall of external auditory canal. The tympanic membrane could not be seen because the mass occluded almost the entire external auditory canal. The mass did not blanch on pneumatic otoscopy. Left – sided otoscopy was normal. Tuning fork tests were consistent with a left conductive hearing loss. Vestibular examination was unremarkable. There was no lymphadenopathy, and the remainder of the head and neck and neurological examination was normal. Audiological evaluation showed a moderate conductive hearing loss in the right ear and normal hearing in the left ear. Non-contrast CT (Fig 1) followed by contrast enhancing CT of mastoid done by 3X3mm axial and coronal section revealed highly enhancing soft tissue shadow in right ear extending from external auditory canal, middle ear and mastoid air cell system.

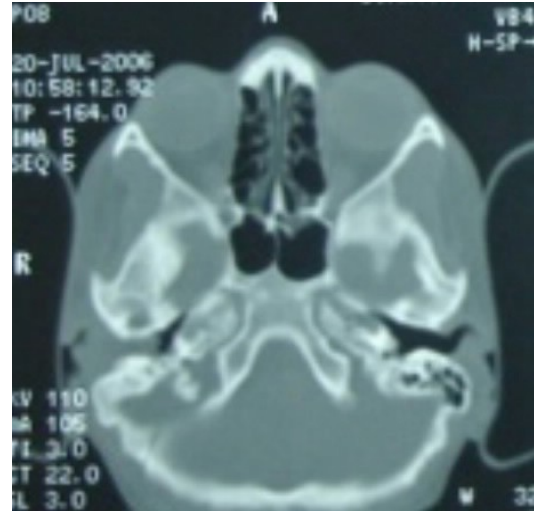


Fig 1: CT scan of the temporal bone showing soft tissue density in external auditory canal, middle ear and mastoid antrum in right ear.

Based on the clinical, audiological and radiological evaluation, the plan of mastoid exploration was made under general anesthesia. The mastoid drilling revealed vascular mass filled the mastoid cavity and surrounding air cell system. The mass from the mastoid was cleared with packing and drilling method. The posterior canal wall was lowered carefully that revealed the continuity of the same mass in the middle ear and external auditory canal with its attachment to the canal wall skin in posterior, superior and some part of the anterior quadrant. At the same time, a medium size central perforation was noted in tympanic membrane. The entire mass was removed carefully along with the involve skin of the external auditory canal. The long process of malleous and lenticular process of incus was eroded while, stapes and facial canal were normal in appearance and position. No other abnormality was found during operation. There was complete cessation of bleeding after clearance of mass. The tympanic membrane perforation was closed with placement of graft over the stapes head. The total amount of blood loss was nearly 200ml. Histopathological report of the specimen revealed capillary hemangioma (Fig 2). The patient had an uneventful postoperative recovery with well-epithelialised cavity within third postoperative months.

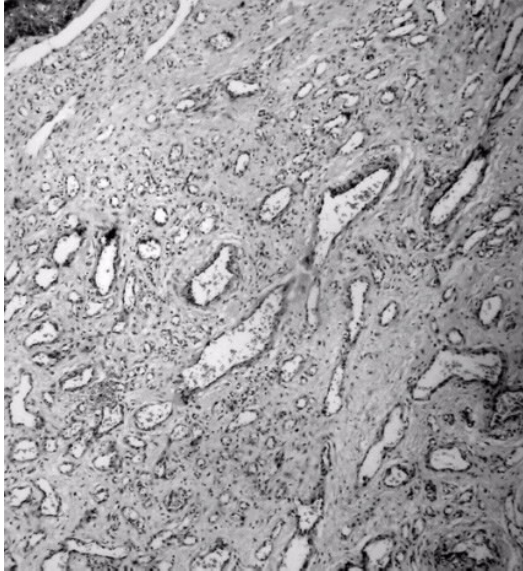


Fig 2: Microscopic picture of the surgical specimen showing features of capillary hemangioma

Discussion:

Hemangiomas are well known benign vascular malformation in head and neck region. However, Intra temporal hemangioma is a rare clinical entity, if occurs, mostly involves inner ear or geniculate ganglion.⁴ The hemangioma of external ear and tympanic cleft is extremely exceptional. Most of the reported cases of such hemangiomas were localized either to the external auditory canal or to middle ear. Tabor J R 1965 has reported a case of intra temporal hemangioma involving middle ear and mastoid.⁵ That was the only case report revealing hemangioma with mastoid involvement, and was treated with modified radical mastoidectomy (MRM). Literature review also revealed no case of hemangioma incorporating external canal, middle ear and mastoid simultaneously. The present case is the first case of hemangioma of such extension.

Hemangiomas typically develop by the age of 1 year in children and involutes by 5 or 6 years of age. Most of the reported cases of external auditory canal and middle ear were diagnosed in adulthood or later in life.¹

Hemangiomas are commonly classified as either capillary or cavernous type. Capillary hemangiomas consist of closely arranged capillary-like channels

while, Cavernous hemangiomas are composed of large cavernous vascular spaces. They are sessile, soft, bright red to blue, on a level with the surface of the skin, or slightly elevated, easily compressible and blench on pressure. Occasionally, pedunculated lesions are formed, attached by a broad-to-slender stalk.^{2,6}

The most common presenting features are conductive hearing loss, pulsatile tinnitus, bloody otorrhoea, otalgia and otitis media in order of decreasing frequency. The tumor may accompanied by infection, and this may present the atypical features.^{1,6} Hetche D A in 2001 has reported a case of right sided tympanic membrane and external auditory canal hemangioma in a 4-month-old girl presented with purulent otorrhoea.⁴ The otoscopic finding in that case revealed purulent discharge, reddish, polypoidal lesion attached to the posterior-superior quadrant of tympanic membrane extending up to the medial portion of external auditory canal and a small central perforation in tympanic membrane.

Most recommended treatment is the complete resection of the mass. However, only one case oh hemangioma of middle ear was reported in English literature underwent spontaneous regression. The recurrence may occur after incomplete resection.^{1,4}

Our case possessed atypical feature. The initial presentation was non-foul smelled, intermittent, purulent, blood staining, increased with upper respiratory tract infection. He also had gradually progressive diminished hearing for last six years. This was due to the presence of concomitant chronic suppurative otitis media in the same year. We did not get the classic picture of hemangioma that compled us to make a clinical diagnosis of CSOM with aural polyp and decided for mastoid exploration. The excessive bleeding tendency of mass with absence of infective feature in mastoid gave the suspicion of vascular lesion that was confirmed by histopathological report. The mass there in mastoid was in the continuity with the same mass found in the middle ear and external auditory canal. In this respect, this is the first case of tympanic cleft hemangioma simultaneously involving external auditory canal, middle ear and mastoid.

References:

1. Tokyol C, Yilmaz MD. Middle ear hemangioma: A case report. *Am J Otolaryngol* 2003; 24:405-407.
2. Reeck JB, Yen TL, Szmit A, Cheung SW. Cavernous Hemangioma of the External Ear Canal. *The Laryngoscope* 2002; 112: 1750-1752.
3. Yang TH, Chiang YC, Chao PZ, Lee FP. Cavernous hemangioma of the body of external auditory canal. *Otolaryngol Head and Neck Surg* 2006; 134: 890-891.
4. Hecht DA, Jackson CG, Grundfast K M. Management of middle ear hemangiomas. *Am J Otolaryngol* 2001; 22: 362-366.
5. Tabor JR. Cavernous hemangioma of the middle ear and mastoid. *Laryngoscope* 1965; 75:673-677.
6. Hiraumi H, Miura M, Hirose T. Capillary hemangioma of the tympanic membrane. *Am J Otolaryngol* 2005; 26:351-352.